

# A stepwise thrombolysis regimen in the management of acute portal vein thrombosis in patients with evidence of intestinal ischaemia

Amine Benmassaoud<sup>1</sup> | Laith AlRubaib<sup>1</sup> | Dominic Yu<sup>2</sup> | Pratima Chowdary<sup>3</sup> |  
Mallika Sekhar<sup>4</sup> | Pathik Parikh<sup>1</sup> | Jemima Finkel<sup>1</sup> | Teik Choon See<sup>5</sup> |  
James O'Beirne<sup>1,6</sup> | Joanna A. Leithead<sup>7</sup> | David Patch<sup>1</sup>

<sup>1</sup>The Royal Free Sheila Sherlock Liver Centre, Royal Free London NHS Trust, London, UK

<sup>2</sup>Department of Radiology, Royal Free London NHS Trust, London, UK

<sup>3</sup>KD Haemophilia and Thrombosis Centre, Royal Free London NHS Trust, London, UK

<sup>4</sup>Department of Haematology, Royal Free London NHS Trust, London, UK

<sup>5</sup>Department of Interventional Radiology, Addenbrooke's Hospital, Cambridge, UK

<sup>6</sup>Department of Hepatology, Sunshine Coast University Hospital, Birtinya, QLD, Australia

<sup>7</sup>Liver Unit, Addenbrooke's Hospital, Cambridge, UK

## Correspondence

Dr. David Patch, Department of Hepatology, Royal Free Hospital, Pond Street, London NW3 2QG, UK.

Email: david.patch@nhs.net

## Funding information

Canadian Association for the Study of the Liver

## Summary

**Background:** Anticoagulation alone in acute, extensive portomesenteric vein thrombosis (PVT) does not always result in spontaneous clot lysis, and leaves the patient at risk of complications including intestinal infarction and portal hypertension.

**Aim:** To develop a new standard of care for patients with acute PVT and evidence of intestinal ischaemia.

**Methods:** We present a case series of patients with acute PVT and evidence of intestinal ischaemia plus ongoing symptoms despite initial systemic anticoagulation, who were treated with a thrombolysis protocol between 2014 and 2019. This stepwise protocol initially uses low-dose systemic alteplase, and in patients with ongoing abdominal pain, and no evidence of radiological improvement, is followed by local clot dissolution therapy (CDT) through a TIPSS. Outcomes and safety were assessed.

**Results:** Twenty-two patients were included. The mean age was 44.6 (standard deviation [SD] 16.0) years, and 64% had an identifiable prothrombotic risk factor. All patients had intestinal wall oedema and 77% had complete occlusion of all portomesenteric veins. Systemic thrombolysis was started 18.7 (SD 11.2) days after the onset of symptoms. 55% of patients underwent TIPSS insertion for CDT. At the end of treatment, symptoms resolved in 91% of patients and recanalisation in 86%. Only one patient required resection for intestinal ischaemia, and there were no deaths. Major complications occurred in two patients (9%).

**Conclusions:** Our stepwise protocol is effective, resulting in good recanalisation rates. It can be commenced early while organising transfer to a centre capable of performing local CDT.

The Handling Editor for this article was Professor Gideon Hirschfield, and it was accepted for publication after full peer-review.

Amine Benmassaoud and Laith AlRubaib are joint co-first authors.

## 1 | INTRODUCTION

The development of acute portomesenteric vein thrombosis (PVT) is associated with significant morbidity and mortality. Its outcome is however unpredictable with 30-day mortality ranging from 0% to 20%.<sup>1,2</sup> This difference likely reflects differences in clot distribution, clot volume, speed of onset and presence of radiological features of intestinal ischaemia. Feared acute complications include intestinal infarction, peritonitis and death from multiorgan failure, while complications related to portal hypertension, such as variceal bleeding and ascites can occur over the long term.<sup>1,3</sup> In order to decrease the risk of acute or chronic complications, it is imperative to reestablish portomesenteric blood flow as soon as possible. Low recanalisation rates and complete occlusion are associated with the development of portal hypertension.<sup>4</sup>

As recommended by the European Association for the Study of Liver (EASL) and the American Association for the Study of Liver, the current mainstay of therapy for acute PVT is anticoagulation with unfractionated (UFH) or low molecular weight heparin (LMWH), in the absence of contraindications.<sup>5,6</sup> This recommendation is based on prospective and retrospective cohort studies, where early anticoagulation led to improved rates of recanalisation.<sup>7</sup> In the EN-Vie prospective study where 102 patients were enrolled, the 1-year recanalisation rates were 38%, 54% and 61% for the portal vein or its branches, the splenic vein and the superior mesenteric vein (SMV) respectively.<sup>8</sup> However, complete recanalisation was less frequent, and only achieved in 19 out of the 95 of patients.<sup>8</sup> In this cohort, the presence of ascites and splenic vein thrombosis was adverse prognostic features. Recanalisation did not occur in the 19 patients with splenic vein thrombosis and ascites.<sup>8</sup> Additional risk factors associated with the failure of recanalisation include complete vessel occlusion, presence of a myeloproliferative disorder and signs of portal hypertension at diagnosis.<sup>9</sup> Although not consistent amongst all studies, the identification of intestinal wall oedema, decreased bowel enhancement, small bowel dilatation and ascites were all associated with increased risk of intestinal infarction and/or resection.<sup>10-12</sup> Therefore, the combination of intestinal wall oedema and ascites in patients with acute PVT and ongoing abdominal pain likely identifies a high risk group in whom optimal management has yet to be established.

In an attempt to improve the outcomes in these high-risk patients, case reports and small case series have described a variety of interventions, including local thrombolysis through a transjugular or transhepatic route.<sup>7</sup> Unfortunately, most of these do not use a standardised protocol and include a small number of patients.<sup>7</sup> Thus, due to the poor level of evidence at this stage, EASL guidelines do not recommend specific therapies beyond therapeutic anticoagulation and suggest expert review where available.<sup>5</sup>

Although the evidence is still heterogeneous in acute PVT, systemic thrombolysis remains an attractive treatment option. Alteplase (tPA), a recombinant human tissue-type plasminogen activator, remains relatively inactive in the circulation and is activated once bound to fibrin converting plasminogen to plasmin.<sup>13</sup> This latter

step accelerates endogenous clot lysis. In the context of arterial events, it is typically instituted with bolus doses with a view to rapid clot lysis and reestablishment of perfusion as in the case of stroke and myocardial infarction.<sup>14-17</sup> There is also growing evidence for its use in massive deep vein thrombosis and submassive pulmonary embolus.<sup>18</sup>

The major side effect of thrombolytic therapy is bleeding, in particular intracranial bleeding. The use of low-dose tPA infusion has been proposed to reduce the risk of treatment-related complications. It is associated with less bleeding complications in the context of acute ischaemic stroke, while it is associated with similar outcome and less complications in patients with acute massive pulmonary embolus.<sup>19,20</sup> As a consequence of the improved safety profile, its use has been extended to the paediatric population in the management of deep vein thrombosis.<sup>21</sup>

Following the death of a patient with acute PVT in our institution, we recognised that there was a therapeutic void in the management of these patients, with no intervention filling the space between anticoagulation, and laparotomy with intestinal resection. We therefore developed a stepwise treatment protocol for patients with indirect evidence of intestinal ischaemia from acute PVT using initial low-dose systemic thrombolysis followed by local thrombolysis through a transjugular portal vein access. In this paper, we present the efficacy and safety of our protocol.

## 2 | METHODS

### 2.1 | Study population

We reviewed all adult patients who were treated with our locally approved stepwise thrombolysis regimen in the context of acute PVT and evidence of intestinal wall oedema between 2014 and 2019 at our centres (Royal Free Hospital, London or Addenbrooke's Hospital, Cambridge, UK). Inclusion and exclusion criteria were pre-determined during the elaboration of the protocol and are described in further detail below.

### 2.2 | Description of portal vein thrombosis and definitions

Diagnosis of PVT was based on contrast-enhanced computed tomography (CT). Cross-sectional imaging was then reviewed by expert radiologists and hepatologists. The extent of thrombosis was described as being either occlusive or non-occlusive, while its location was based on its anatomical location, including the main portal vein, its right and left branches, splenic vein and SMV. Other important radiological findings such as the presence of cavernomatous transformation or portosystemic collaterals, ascites, intestinal wall oedema with "halo" appearance, pneumatosis intestinalis and pneumoperitoneum were recorded.<sup>22</sup> Although intended for patients with cirrhosis, the recently proposed Sarin anatomico-functional classification of PVT was used to describe the clot burden.<sup>23</sup>

## 2.3 | Treatment protocol

### 2.3.1 | Patient selection for systemic thrombolysis

Our treatment protocol is described below, and is summarised in Figure 1. All patients had to have been initially treated with anticoagulation therapy alone, as standard of care. Patients with acute PVT with ongoing abdominal pain and persistent evidence of intestinal wall oedema, in the absence of perforation, despite anticoagulation alone were transferred to our centre and considered for treatment with our low-dose systemic thrombolysis protocol. PVT was considered acute if patients had ongoing abdominal pain which started within the last 30 days. Patients with evidence of cavernomatous transformation were excluded from this reported series. Patients were also excluded if they had cirrhosis, evidence of malignancy on initial cross-sectional imaging or a contraindication to thrombolysis including major surgery within the preceding 2 weeks, central nervous system surgery or ischaemia with bleeding within preceding 4 weeks, previous cerebral haemorrhage in the preceding 12 months, current active bleeding, allergic reaction to thrombolytic, fibrinogen under 1.0 g/L or platelet count under  $50\,000 \times 10^9/L$ .

### 2.3.2 | Systemic thrombolysis protocol

Written and informed consent was obtained from all patients before initiation of our protocol. Patients were admitted to a "High-Care" area on the Hepatology ward, under the care of hepatologists. An early request for a peripherally inserted central venous catheter was made. Intravenous tPA was started at a dose of 0.05 mg/kg/h, up to a maximum of 4 mg/h for 72 hours. Initially all patients received concomitant UFH at a dose of 12 units/kg/h. A weight-based nomogram was followed for dose adjustment of the UFH infusion to target activated partial thromboplastin time (aPTT) ratio  $<1.8$ . Because of difficulties achieving target aPTT ratios, the protocol was subsequently amended and LMWH replaced UFH. Tinzaparin was used at a dose of 100 units/kg injected subcutaneously twice daily. Tinzaparin therapy was adjusted to maintain an anti-Xa peak level between 0.5 and 0.6 U/mL and a trough of 0.3 U/mL. The protocol was evaluated and passed by the hospital's Drug and Therapeutics Committee.

### 2.3.3 | Safety monitoring of systemic thrombolysis

Patients were frequently monitored for bleeding from any site, including sites of venipuncture and indwelling catheters. Blood samples were obtained three times per day and included a full blood count, fibrinogen level, aPTT ratio, prothrombin time, international normalised ratio (INR), liver enzymes, urea and electrolytes and anti-Xa level when appropriate. Thrombolysis infusion was stopped if fibrinogen was under 1.0 g/L, platelet count  $<50\,000 \times 10^9/L$ , continuous bleeding from venipuncture site, or massive haemorrhage. Alteplase could be reinitiated at 50% of the previous dose once the fibrinogen level was above 1.0 g/L unsupported.

### 2.3.4 | Efficacy monitoring of systemic thrombolysis

Infusion of tPA was planned to continue for 72 hours and up to 7 days. Re-evaluation of the PVT with contrast-enhanced CT was repeated after 48-72 hours of thrombolysis or earlier if there was a change in the patient's condition.

### 2.3.5 | Patient selection for local CDT

Following repeat cross-sectional imaging at 48-72 hours, patients with ongoing abdominal pain and persistent evidence of intestinal ischaemia or lack of improvement in clot burden were considered for local clot dissolution therapy (CDT) after discussion between Interventional Radiology and Hepatology during multidisciplinary meetings. In patients with early symptomatic response and evidence of radiological improvement, systemic tPA was continued for up to 7 days.

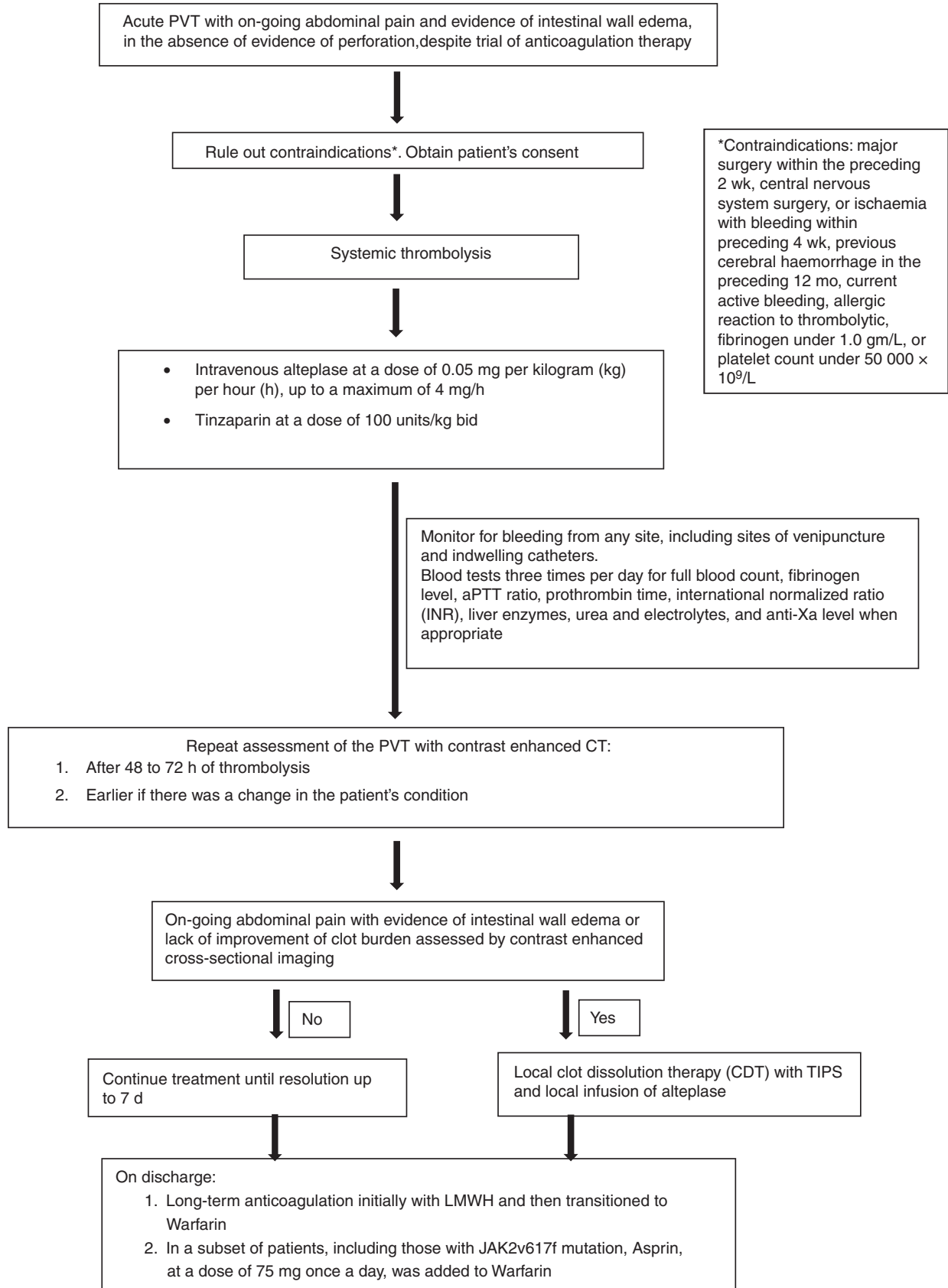
### 2.3.6 | Local CDT protocol

Written and informed consent was obtained from patients before proceeding with any local CDT. All procedures were performed under general anaesthesia. Systemic thrombolysis and anticoagulation were interrupted for a minimum of 4 hours ahead of the intervention. Local CDT was performed using a transjugular approach with creation of an intrahepatic portosystemic shunt (TIPSS). An ultrasound-assisted technique was used to facilitate TIPSS insertion, as described in a previous publication.<sup>24</sup> The rest of the TIPSS insertion technique did not differ from established standards.<sup>25</sup> Once the covered stent was deployed, local thrombolysis was performed using fountain catheters or conventional catheters with infusion of tPA at a dose of 1 mg/h until satisfactory improvement. Mechanical or aspiration thrombectomy was performed using the EKOS system (BTG Interventional Medicine), Angiojet peripheral thrombectomy system (Boston Scientific), Trellis system (Medtronic) or Penumbra system (Penumbra Inc), as available. Following this, sedation was weaned and patients were extubated but transjugular central venous access was maintained for 24 hours to allow direct portal angiography on the following day. Re-intervention was performed at the same time with CDT if judged necessary based on the angiography results.

## 2.4 | Outpatient follow-up

Following treatment for acute PVT, patients were discharged on long-term anticoagulation initially with LMWH and then transitioned to Warfarin. In a subset of patients, including those with JAK2v617f mutation, Aspirin was added at a dose of 75 mg once a day. Abdominal ultrasound with Doppler or contrast-enhanced CT was performed regularly, with subsequent angiography or TIPSS re-intervention as dictated by clinical picture.

Low-dose systemic thrombolysis in the treatment of acute portomesenteric venous thrombosis (PVT) with evidence of intestinal ischemia



**FIGURE 1** Stepwise thrombolysis protocol for acute extensive portal vein thrombosis

## 2.5 | Investigation for haematological disorder

All patients were screened for inherited or acquired haematological disorders at the time of presentation and at follow-up, as determined by Haematology. Investigations for myeloproliferative diseases included analysis for *JAK2v617f* and calreticulin mutations; bone marrow biopsy was performed in the stable phase if necessary. Investigations for thrombophilia included Factor V Leiden mutation, MTHFR mutation, prothrombin gene mutation, antithrombin III deficiency, protein C and S deficiency, Factor VIII, lupus anticoagulant, cardiolipin antibodies, flow cytometry for paroxysmal nocturnal haemoglobinuria.

## 2.6 | Study outcomes

### 2.6.1 | Efficacy outcomes

Our main outcome included the resolution of abdominal pain during hospital admission and recanalisation of the portal system. Recanalisation of the portal system was classified as complete, partial or absent. Complete recanalisation referred to complete absence of thrombus as determined by contrast-enhanced CT or direct portal angiography, while partial recanalisation was defined as the improvement in clot burden without complete recanalisation. Absent recanalisation meant that there was no improvement in the clot burden despite receiving therapy. Recanalisation was assessed at the end of the hospital admission for acute PVT after all therapeutic interventions were completed, as described above. Need for surgical intervention and loss of vessel patency during follow-up were also recorded.

### 2.6.2 | Safety outcomes

Protocol safety was assessed in all patients and was divided into major and minor complications. A major complication was defined as any complication which resulted in an increase in the level of care, such as need for surgical intervention, bleeding requiring blood transfusion, septic complications requiring antibiotic therapy, and death. Minor complications were comprised of any other complication which was self-limiting or not classified as above. Treatment interruption for safety concerns was also recorded.

## 2.7 | Statistical analysis

Descriptive analysis was performed. Baseline characteristics were expressed as mean (standard deviation [SD]) or median (interquartile range [IQR]) depending on the distribution characteristics, or numbers (%) for categorical variables, unless otherwise specified. Normal distribution was assessed using the Kolmogorov-Smirnov test. Logistic regression analysis was performed in order to identify predictors of failed recanalisation. Kaplan-Meier curve was constructed to show loss of vessel patency over time in patients who achieved recanalisation, with log-rank test to identify difference

between those with underlying thrombotic risk factor and those without. Two-tailed *P*-value of .05 was used to determine statistical significance. Data were analysed using SPSS (version 25; IBM).

## 3 | RESULTS

A total of 22 patients with acute PVT, evidence of intestinal wall oedema with "halo" appearance, and ongoing symptoms despite anticoagulation therapy were treated with systemic thrombolysis at our centres using the protocol described above between 2014 and 2019 (Figure 2). The overall median follow-up was 16.9 (SD 14.1) months. The average patient age was 44.6 (SD 16.0) years and six (27.3%) were female. A predisposing risk factor was identified in 14 (63.6%) patients, including 11 (50.0%) with a haematological disorder. Five patients were found to have a *JAK2v617f* mutation, while two had Factor V Leiden mutation, two had a MTHFR mutation and two had prothrombin gene mutation. Three patients had a local risk factor. One patient was subsequently diagnosed with a colonic malignancy 8 months after presenting with acute PVT. All patients presented with abdominal pain, while 11 (50.0%) also presented with vomiting, and seven (31.8%) with constipation. The median duration of symptoms prior to presentation was 12 (IQR 14.2) days, while the average duration from symptom initiation to start of systemic thrombolysis was 18.7 (SD 11.2) days. Ascites was present in 14 (63.6%) patients. Table 1 contains further baseline information.

### 3.1 | Extent of PVT

The main portal vein was completely occluded in 19 (86.4%) patients, while the SMV was completely occluded in 21 (95.5%), and the splenic vein in 18 (81.8%). Overall, 17 (77.3%) patients had complete occlusion of all major segments of the portomesenteric system, including the portal vein, its branches, the splenic vein and the SMV. Simultaneous complete occlusion of the portal vein and SMV was present in 19 (82.6%) patients. One patient who had a history of deep vein thrombosis presented with complete occlusion of the SMV alone, intestinal oedema and ascites. At presentation, collaterals were noted in nine (40.9%) patients. No patient had a cavernoma at presentation. The Sarin anatomico-functional classification of portal vein thrombosis at baseline was used and is shown in Table 2.<sup>23</sup>

### 3.2 | Treatment of PVT

All 22 patients included received low-dose systemic thrombolysis with tPA (Table 3). The median interval between in-hospital diagnosis of PVT and initiation of systemic thrombolysis was 4 (IQR 4) days. The median treatment duration with systemic tPA was 3.4 (IQR 2.7) days. As per standard of care, all patients continued to receive systemic anticoagulation with either UFH or LMWH.

In the early phase of therapy after systemic thrombolysis and anticoagulation, recanalisation occurred in 8 (36%) patients, of which

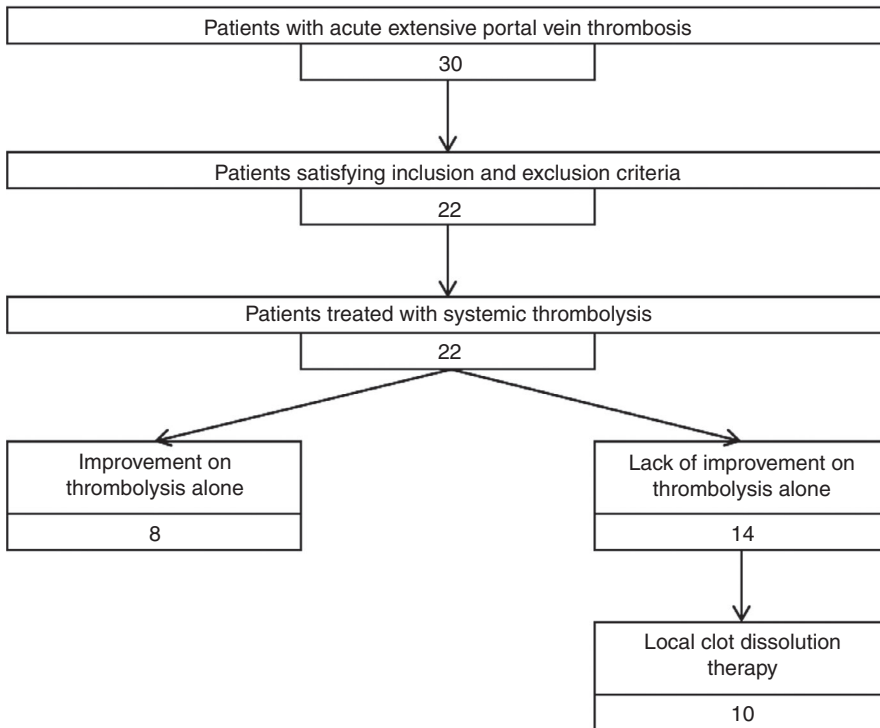


FIGURE 2 Patient flow chart

Excluded patients (n = 8):

No evidence of intestinal ischemia (n = 2)

Evidence of cirrhosis (n = 2)

Contraindication to systemic thrombolysis (n = 3)

Evidence of concomitant hepatic vein thrombosis (n = 1)

four were partial and three were complete, while symptoms resolved in eight (36.4%) patients (Figure S1). In the remaining 14 patients, 11 underwent successful TIPSS insertion for escalation of therapy, while it was technically not possible in two, and lack of interventional support prevented insertion in the third.

In the 11 patients where TIPSS was successfully deployed, 10 received CDT. One patient did not receive local therapy as procedural portal angiography showed interval improvement in the portomesenteric flow, and further intervention was not felt to be required. This patient experienced symptom resolution with complete recanalisation. All 10 patients treated with CDT experienced resolution of symptoms and recanalisation of their portomesenteric system which was partial in three (30%) and complete in seven (70%) patients (Figure S2).

A median of 3.5 (IQR 2) CT scans per patient was required during their in-patient stay. For those who underwent TIPSS insertion, a median of 3 (IQR 2) procedures requiring portal angiography was performed per patient.

### 3.3 | Efficacy outcome

Following treatment with systemic thrombolysis with or without local CDT, 20 (90.9%) patients experienced resolution of abdominal pain. At least partial recanalisation occurred in 19 (86.4%) patients with complete recanalisation in 11 (50%) patients as shown

in Table 4. Of the 17 patients with complete obstruction of all portomesenteric veins in our study, 14 (82.4%) patients had at least partial recanalisation, with complete recanalisation in seven (41.2%) patients. Of the 11 patients with both splenic vein obstruction and ascites in our study, at least partial recanalisation occurred in nine (81.8%) patients, with complete recanalisation in four (36.4%).

Three (13.6%) patients underwent surgical intervention. Only one (4.3%) required surgery due to failure of therapy. The second patient required surgery to correct a strangulated umbilical hernia 30 days after presentation, while the third patient underwent surgery to resect an ischaemic stricture which was described on initial imaging.

Predictors of failed recanalisation were investigated, but univariate logistic regression analysis did not identify a statistically significant variable, including underlying haematological disorder, duration of symptoms before initiation of therapy, presence of collaterals at diagnosis or location of thrombus.

### 3.4 | Recurrent thrombosis or bleeding

Three patients who had initially achieved recanalisation developed recurrent thrombosis following treatment of the acute episode. Two of these events were related to interruption of anticoagulation, while the third was in the context of later identification of colon cancer. No patients developed bleeding from portal hypertensive

causes during follow-up. There was no difference in loss of vessel patency between patients with underlying prothrombotic condition and those without.

**TABLE 1** Baseline patient characteristics

	Whole cohort (n = 22)
Age in years, mean (SD)	44.6 (16.0)
Gender, M/F, n	16/6
Follow-up in months, mean (SD)	16.9 (14.1)
Weight in kg, mean (SD)	88.4 (19.4)
Prothrombotic risk factor, n (%)	14 (63.6)
Haematological disorder	11 (50)
Local	3 (13.6)
Symptoms, n (%)	
Abdominal pain	22 (100)
Vomiting	11 (50)
Constipation	7 (31.8)
Diarrhoea	5 (22.7)
Leucocyte count in g/L, mean (SD)	12.0 (5.6)
C-reactive protein in mg/dL, mean (SD)	106.0 (69.8)
Presence of intestinal wall oedema, n (%)	22 (100)
Ascites, n (%)	14 (63.9)
Duration of symptoms prior to presentation in days, median (IQR)	12 (14.2)
Duration of symptoms to treatment in days, mean (SD)	18.7 (11.2)
Number of CT scans during admissions, median (IQR)	3.5 (2)

Note: Numbers expressed as n (%) and median (IQR).  
Abbreviation: IQR: interquartile range.

**TABLE 2** Anatomico-functional description of the portal vein thrombosis at baseline

	Whole cohort (n = 22)
Site of PVT	
Type 1: only trunk	0
Type 2: only branch: 2b, both branches	1 (4.5)
Type 3: trunk and branches	20 (90.9)
Degree of PVT occlusion	
Occlusive	19 (86.4)
Non-occlusive	3 (13.6)
Duration and presentation	
Recent, symptomatic, acute intestinal ischaemia	22 (100)
Extent of PV system occlusion	
Splenic vein	18 (81.8)
Superior mesenteric vein	21 (95.5)
Both	18 (81.8)

Note: Numbers expressed as n (%).  
Abbreviations: PV, portal vein; PVT, portal vein thrombosis.

### 3.5 | Safety outcome

A total of nine (40.9%) patients suffered from complications, seven (31.8%) of which were minor complications. In the initial phase of therapy with systemic low-dose thrombolysis, there were no major complications. All minor complications were related to bleeding from different sites, including epistaxis, haematuria, oral mucosa and sites of venipuncture. Major complications occurred in two patients. The first patient developed a subcapsular haematoma, in the context of a difficult TIPSS insertion, and, 6 months later, TIPSS-related encephalopathy which resolved after shunt closure. The second patient suffered from a neck haematoma related to jugular vein puncture. Both patients recovered from these complications. Importantly, no one developed intracranial bleeding.

Systemic thrombolysis was interrupted in eight (36.4%) patients. Of these, four patients required interruption in the first 72 hours with partial recanalisation in two and complete recanalisation in two. Reasons for treatment interruption included low fibrinogen in one, minor complications in two, and need for surgical intervention for intestinal ischaemia in the last. In the other four cases, treatment had to be completely stopped in only one patient (due to oral mucosal bleed), whereas the other were able to resume therapy. There was no mortality recorded during the acute treatment phase or follow-up.

## 4 | DISCUSSION

Acute and extensive PVT is a condition with a varying degree of severity.<sup>1</sup> Similar to other conditions where acute thrombosis can lead to infarction and potentially death, a stepwise evidence-based approach is critical to improve outcomes. Unfortunately, data in patients with PVT specifically are heterogenous and randomised controlled studies are absent. Current guidelines recommend the use of therapeutic



	Whole cohort (n = 22)
Time from diagnosis to initiation of systemic thrombolysis, in days, median (IQR)	4 (4)
Anticoagulation (UFH or LMWH)	22 (100)
Systemic tPA	22 (100)
Duration of systemic tPA infusion, in days, median (IQR)	3.4 (2.7)
TIPSS	11 (50)
Local tPA	10 (45.5)
Mechanical thrombolysis	10 (45.5)

**TABLE 3** Description of treatment received

Numbers expressed as n (%), median (IQR), or mean (SD).

Abbreviations: LMWH, low molecular weight heparin; TIPSS, transjugular intrahepatic portosystemic shunt; tPA, alteplase; UFH, unfractionated heparin.

**TABLE 4** Description of treatment efficacy

	Whole cohort (n = 22)
Symptom resolution	20 (90.9)
Recanalisation	
Any	19 (86.4)
Complete	11 (50.0)
Absence	3 (13.6)

Numbers expressed as n (%).

anticoagulation with UFH or LMWH. But when stratified based on the extent of thrombosis, anticoagulation alone leads to inadequate rates of recanalisation, leaving a therapeutic void. Consequently, in patients with intestinal congestion and imminent infarction, treatment strategies remain experimental. Here, we present the efficacy and safety of a stepwise treatment protocol for patients with acute PVT with features suggestive of failure of standard of care. We observe that low-dose systemic thrombolysis and CDT resulted in at least partial recanalisation in 86%, and complete recanalisation in 50%. Only one patient required intestinal resection; and the survival rate was 100%.

Our stepwise protocol was specifically designed to select patients at a high risk of poor outcome based on known and validated risk factors, such as extensive thrombosis with mesenteric and splenic involvement, presence of ascites and radiological evidence of intestinal ischaemia.<sup>8,26</sup> We recognise that the radiological findings of intestinal ischaemia can be nonspecific, but all of our patients had intestinal wall oedema with "halo" appearance. More advanced changes, such as pneumatosis intestinalis, probably reflect irreversible ischaemia.<sup>22</sup> Seventy-seven per cent of our patients had complete and simultaneous occlusion of the portal vein, its branches, the SMV and splenic veins. Patients had indirect evidence of intestinal ischaemia with wall oedema in all and ascites in 64% of patients. This separates our study from previous reports, where patients did not have such severe disease burden.<sup>27</sup>

Although the idea of thrombolysis in patients with acute PVT is not recent, it has not gained acceptance due to an unfavourable balance of efficacy and safety. Before 2017, the largest cohort of thrombolysis in acute portal or mesenteric vein thrombosis included 16 patients

accrued over 11 years.<sup>28</sup> In this group of patients, only one (6%) patient had complete clot resolution. In addition, the rate of major complication was 60%, including death related to intestinal haemorrhage and sepsis.

The report by Klinger et al shared an interesting thrombolysis protocol.<sup>27</sup> They employed a rapidly invasive approach using a transjugular TIPSS puncture set to gain access to the right portal vein branch. Once in the portal vein, mechanical thrombectomy and CDT were performed. An intensive daily angiographic assessment of the clot burden guided ongoing therapy and required intensive care unit admission. In their cohort of 17 patients, only 12 patients had SMV involvement, and it is not mentioned how many had complete and simultaneous occlusion of all segments. In addition, only 10 (59%) had signs of intestinal ischaemia. Although their protocol did lead to high rates of recanalisation, patients did not seem to be as severely affected as ours with similar complication rates. Furthermore, their protocol requires a very high intensity level of health care resource availability which may limit its practicability.

Our case series included patients at high risk of poor outcome, and becomes the largest study using a pre-established thrombolysis protocol with 22 patients. The strength of our protocol is that it also provided a second level of therapeutic intervention for patients failing initial therapy with systemic thrombolysis, with long-term follow-up. Although lower than in the study by Klinger et al who relied on early invasive thrombolytic therapy, our overall rate of recanalisation was 86.4% with complete recanalisation in 50%. We were not able to identify predictors of failed recanalisation with our protocol as opposed to other studies with similar number of patients. Although this might mean that our protocol is more generally applicable, it is more likely to be related to our small sample size. We used a low dose of tPA in order to limit potential bleeding complications. Overall, major complications occurred in two (9%) patients which are lower than reported rates of complications with thrombolysis.<sup>7,27,28</sup> Of note, none of our major complications occurred during the early phase of treatment with thrombolysis alone and no patient suffered from an intracranial bleed. In our experience, the use of low-dose systemic thrombolysis mainly led to small oozing from cannula sites. We therefore believe that our thrombolysis protocol provides an effective treatment approach option for patients with acute PVT at high risk of poor outcome from



anticoagulation alone. The added benefit of our protocol is that it has the potential of being used in centres able to provide early safe systemic thrombolysis while discussing the case with nearby centres capable of local CDT. Once efficacy is reassessed at 48-72 hours, patients who have failed initial treatment can then be transferred for second level of therapeutic intervention with local CDT. This would be analogous to the drip-and-ship approach used in acute stroke.<sup>29</sup>

Our study has its limitations which are mainly related to its small size and therefore associated subgroup heterogeneity. The lack of a randomised control arm also decreases our ability to compare components of our protocol. Unfortunately, this is the reality in a condition with a low overall incidence, associated with significant morbidity and mortality, and limited therapeutic options. In addition, despite our best efforts at identifying patients at high risk of unfavourable outcome with anticoagulation alone, the literature reports inconsistent poor initial prognostic factors where nonsurgical therapies might still have a role. Furthermore, the optimal duration of anticoagulation alone before escalating to salvage therapy is unknown.<sup>30</sup> In our study, the average duration before initiation of our protocol was 4 days. It is our impression that longer intervals would be associated with decreased chance of recanalisation leaving the patient at risk of progressive intestinal ischaemia and long-term sequelae of portal hypertension. Lastly, although the idea of TIPSS insertion in patients with no underlying liver disease is controversial, it allows delivery of mechanical thrombectomy and infusion of local thrombolysis while it also improves portal haemodynamics by decreasing portal pressure and increasing flow out of the splanchnic circulation.

In conclusion, we have shown that our stepwise thrombolysis protocol is effective at providing high rates of recanalisation despite initial indicators of poor outcome. This is the largest available cohort using thrombolysis in a patient population which at the moment suffers from a lack of a standardised care pathway and we would hope that our protocol can be utilised and validated in other centres.

## ACKNOWLEDGEMENTS

*Declaration of personal interests:* LA, AB, PC, JF, JL, JO, DP, PP, MS, TS, DY do not have any potential conflict of interest to disclose.

*Personal and funding interests:* Dr Amine Benmassaoud was supported by an educational grant from the Canadian Association for the Study of the Liver.

## AUTHORSHIP

*Guarantor of the article:* Dr David Patch.

*Author contributions:* AB and LA are co-first authors, and have contributed to study concept and design, acquisition of data, analysis and interpretation of data, drafting of manuscript, critical revision of manuscript and statistical analysis. PC, JF, JO, PP, MS, TS, DY have contributed to study concept and design and critical revision of the manuscript. JL has contributed to study concept and design, acquisition of data, critical revision of the manuscript and administrative,

technical and material support. DP has contributed to study concept and design, acquisition of data, analysis and interpretation of data, critical revision of manuscript, administrative, technical and material support, study supervision.

All authors have approved the final draft of the manuscript.

## ORCID

Amine Benmassaoud  <https://orcid.org/0000-0002-0202-2276>

David Patch  <https://orcid.org/0000-0002-8399-4017>

## REFERENCES

1. Singal AK, Kamath PS, Tefferi A. Mesenteric venous thrombosis. *Mayo Clin Proc.* 2013;88:285-294.
2. Sogaard KK, Darvalics B, Horvath-Puho E, Sorensen HT. Survival after splanchnic vein thrombosis: a 20-year nationwide cohort study. *Thromb Res.* 2016;141:1-7.
3. Noronha Ferreira C, Seijo S, Plessier A, et al. Natural history and management of esophagogastric varices in chronic non-cirrhotic, nontumoral portal vein thrombosis. *Hepatology.* 2016;63:1640-1650.
4. Maldonado TS, Blumberg SN, Sheth SU, et al. Mesenteric vein thrombosis can be safely treated with anticoagulation but is associated with significant sequelae of portal hypertension. *J Vasc Surg Venous Lymphat Disord.* 2016;4:400-406.
5. European Association for the Study of the Liver. EASL Clinical Practice Guidelines: vascular diseases of the liver. *J Hepatol.* 2016;64:179-202.
6. DeLeve LD, Valla DC, Garcia-Tsao G; American Association for the Study Liver Diseases. Vascular disorders of the liver. *Hepatology.* 2009;49:1729-1764.
7. Hall TC, Garcea G, Metcalfe M, Bilku D, Dennison AR. Management of acute non-cirrhotic and non-malignant portal vein thrombosis: a systematic review. *World J Surg.* 2011;35:2510-2520.
8. Plessier A, Darwish-Murad S, Hernandez-Guerra M, et al. Acute portal vein thrombosis unrelated to cirrhosis: a prospective multi-center follow-up study. *Hepatology.* 2010;51:210-218.
9. Ravichandran P, Croome KP, Kovacs MJ, Lazo-Langner A, Hernandez-Alejandro R. Initial management of noncirrhotic splanchnic vein thrombosis: when is anticoagulation enough? *Can J Gastroenterol Hepatol.* 2014;28:207-211.
10. Salim S, Ekberg O, Elf J, Zarrouk M, Gottsater A, Acosta S. Clinical implications of CT findings in mesenteric venous thrombosis at admission. *Emerg Radiol.* 2018;25:407-413.
11. Cho JW, Choi JJ, Um E, et al. Clinical manifestations of superior mesenteric venous thrombosis in the era of computed tomography. *Vasc Specialist Int.* 2018;34:83-87.
12. Nuzzo A, Maggiori L, Ronot M, et al. Predictive factors of intestinal necrosis in acute mesenteric ischemia: prospective study from an intestinal stroke center. *Am J Gastroenterol.* 2017;112:597-605.
13. Deitcher SR, Jaff MR. Pharmacologic and clinical characteristics of thrombolytic agents. *Rev Cardiovasc Med.* 2002;3(Suppl 2):S25-33.
14. GUSTO investigators. An international randomized trial comparing four thrombolytic strategies for acute myocardial infarction. *N Engl J Med.* 1993;329:673-682.
15. Late Assessment of Thrombolytic Efficacy (LATE) study with alteplase 6-24 hours after onset of acute myocardial infarction. *Lancet.* 1993;342:759-766.
16. Jerjes-Sanchez C, Ramirez-Rivera A, Arriaga-Nava R, et al. High dose and short-term streptokinase infusion in patients with

- pulmonary embolism: prospective with seven-year follow-up trial. *J Thromb Thrombolysis*. 2001;12:237-247.
17. National Institute of Neurological Disorders and **Stroke** rt-PA **Stroke** Study Group. Tissue plasminogen activator for acute ischemic stroke. *N Engl J Med*;1995;333:1581-1587.
  18. Streiff MB, Agnelli G, Connors JM, et al. Guidance for the treatment of deep vein thrombosis and pulmonary embolism. *J Thromb Thrombolysis*. 2016;41:32-67.
  19. Anderson CS, Robinson T, Lindley RI, et al. Low-dose versus standard-dose intravenous alteplase in acute ischemic stroke. *N Engl J Med*. 2016;374:2313-2323.
  20. Piazza G, Hohlfelder B, Jaff MR, et al. A prospective, single-arm, multicenter trial of ultrasound-facilitated, catheter-directed, low-dose fibrinolysis for acute massive and submassive pulmonary embolism: the SEATTLE II study. *JACC Cardiovasc Interv*. 2015;8:1382-1392.
  21. Leary SE, Harrod VL, de Alarcon PA, Reiss UM. Low-dose systemic thrombolytic therapy for deep vein thrombosis in pediatric patients. *J Pediatr Hematol Oncol*. 2010;32:97-102.
  22. Kanasaki S, Furukawa A, Fumoto K, et al. Acute mesenteric ischemia: multidetector CT findings and endovascular management. *Radiographics*. 2018;38:945-961.
  23. Sarin SK, Philips CA, Kamath PS, et al. Toward a comprehensive new classification of portal vein thrombosis in patients with cirrhosis. *Gastroenterology*. 2016;151:574-577.e3.
  24. Tavare AN, Wigham A, Hadjivassilou A, et al. Use of transabdominal ultrasound-guided transjugular portal vein puncture on radiation dose in transjugular intrahepatic portosystemic shunt formation. *Diagn Interv Radiol*. 2017;23:206-210.
  25. Owen AR, Stanley AJ, Vijayanathan A, Moss JG. The transjugular intrahepatic portosystemic shunt (TIPS). *Clin Radiol*. 2009;64:664-674.
  26. Condat B, Pessione F, Helene Denninger M, Hillaire S, Valla D. Recent portal or mesenteric venous thrombosis: increased recognition and frequent recanalization on anticoagulant therapy. *Hepatology*. 2000;32:466-470.
  27. Klinger C, Riecken B, Schmidt A, et al. Transjugular local thrombolysis with/without TIPS in patients with acute non-cirrhotic, non-malignant portal vein thrombosis. *Dig Liver Dis*. 2017;49:1345-1352.
  28. Hollingshead M, Burke CT, Mauro MA, Weeks SM, Dixon RG, Jaques PF. Transcatheter thrombolytic therapy for acute mesenteric and portal vein thrombosis. *J Vasc Interv Radiol*. 2005;16:651-661.
  29. Holodinsky JK, Williamson TS, Kamal N, Mayank D, Hill MD, Goyal M. Drip and ship versus direct to comprehensive stroke center: conditional probability modeling. *Stroke*. 2017;48:233-238.
  30. Hernandez-Gea V, De Gottardi A, Leebeek F, Rautou PE, Salem R, Garcia-Pagan JC. Current knowledge in pathophysiology and management of Budd-Chiari syndrome and non-cirrhotic non-tumoral splanchnic vein thrombosis. *J Hepatol*. 2019;71:175-199.

## SUPPORTING INFORMATION

Additional supporting information will be found online in the Supporting Information section at the end of the article.

**How to cite this article:** Benmassaoud A, AlRubaiy L, Yu D, et al. A stepwise thrombolysis regimen in the management of acute portal vein thrombosis in patients with evidence of intestinal ischaemia. *Aliment Pharmacol Ther*. 2019;50:1049-1058. <https://doi.org/10.1111/apt.15479>